

**Author: Adel Ekladios\***

Faculty of Health and Medical Sciences, Internal Medicine, University of western Australia, Australia

\***Corresponding author:** Adel Ekladios, Clinical Associate professor of Medicine, University of Western Australia, Faculty of Health and Medical Sciences, Australia, E-mail: [adel ekladios@health.wa.gov.au](mailto:adel ekladios@health.wa.gov.au)

**Received:** November 01, 2020; **Accepted:** November 9, 2020; **Published:** November 11, 2020

**Copyright:** ©2020 Adel Ekladios. This is an open-access article distributed under the terms of the Creative Commons Attribution License, which permits unrestricted use, distribution, and reproduction in any medium, provided the original author and source are credited.

## CASE REPORT

Stroke is a serious disease which can lead to significant disability, [1] most of stroke is preceded by transient ischemic attack [2], diagnosing TIA in timely manner is of Para amount importance as 10% of patient diagnosed with TIA will develop stroke in two weeks, [3], It is important to confirm the diagnosis and rule out stroke mimics like migraines aura, transient Global Amnesia, syncope, hypoglycemia, delirium, seizure [4] functional disorder, demyelination, and intracranial tumor, treating TIA can prevent stroke [4] cardio embolic TIA due to AF can be prevented with anticoagulation, TIA due to critical stenosis of extra cranial carotid stenosis can be treated with revascularizations [5], Uncommon TIA or stroke due posterior reversal loco encephalopathy (PRESS) and posterior reversible vasoconstriction syndrome, can be treated with controlling blood pressure [6], further more diagnosed TIA lead to starting secondary prevention,(anti platelet , statin, antihypertensive and modified life style) [7] which prevent stroke in the future.

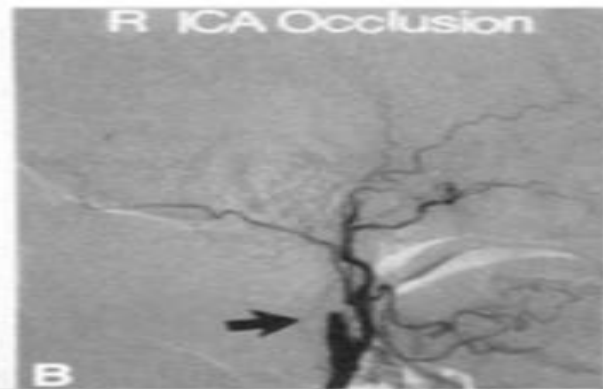
Definition of TIA is sudden, focal and temporary loss of function in brain, retinal and spine [8], 85% of strokes are ischemic, and 15% are hemorrhagic, uncommon causes of stroke are dissection, infective endocarditis, vasculitis, trauma, anticoagulation, hypertensive encephalopathy, eclampsia, Drugs like amphetamine and cocaine and brain tumor [9]. We presenting a patient with a very rare type of Transient Ischemic Attack, 77-year-old mechanic presented with frequent episodes of rhythmic jerky movements of his left arm and leg when he tries to examine underneath the car, immediate sitting will abort all his symptoms, No impairment of consciousness, his medical history is noted for well controlled hypertension, on thiazide, hypercholesterolemia controlled on Lipitor 10mg.

Has a family history of generalized epilepsy, his sister diagnosed with clinically isolated demyelinating syndrome under regular follow up with MS specialist, patient seen in first seizure clinic, examination in detail was unremarkable, Blood pressure was 125/70 with no postural drop, no murmurs, no carotid bruit, and regular pulse and no focal neurological signs, he was given a diagnosis of focal seizure, the following investigation was ordered, full blood count, ESR, CRP, thyroid function, autoimmune screen, HBA1c , coagulation screen, thrombophilia screen, serum B12, methyl malonic acid and homocysteine ,serum copper and zinc , serum vitamin E and C level, vasculitis screen , urine A/C ratio , EEG, MRI, MRA of head and spine, ECG, 24-hour blood pressure monitoring, 7 days Holter monitor, transthoracic ECHO, Patient was advised not to drive for 6 months and to be seen in the clinic in 3 months' time, Patient was seizure free, all above mentioned blood tests, imaging for the brain and spine, EEG, Holtermonitor were either normal or negative, transthoracic echo showed small PFO, transesophageal echo confirmed non hemodynamic PFO.

Patient was advised to go back for work and driving with follow up with his GP, next day patient went to work , his symptoms came back when he started to inspect underneath cars, seen by his GP who arranged an urgent appointment with his movement disorder specialist, repeated MRI, MRA, stroke protocol and EEG were absolutely normal, patient was admitted to the hospital under neurology department, repeated system in and neurological examination was unremarkable, patient was kept in the hospital for 7 days and connected to EEG electrodes for continuous monitoring, which did not show any epileptogenic activity during his stay in the hospital, before discharge patient was asked to show how he examine the underneath of the car, once patient start to show how he checks on the underneath car , his shaking of right arm and leg came back , EEG was absolutely unremarkable with no epileptic activity , it was noted that patient extend his neck during checking on cars.

Patent admitted to the Cath lab and went for PET and SPECT Scan with IV Acetamide and transcranial Doppler. Which confirmed hypo perfusion in the right extra cranial carotid vessel, cerebral Angio confirmed hemodynamic significant stenosis of the right external carotid artery and distal part of the right internal carotid artery, stenting of the right external

carotid artery showed significant improvement and resolution of all symptoms, Patient resumed his work with no further symptoms, limb-shaking TIA is a rare hemodynamic TIA which confused general physicians and neurologist with focal seizure, also what adds to the complexity is ischemia cause scar and subsequently seizure, especially in elderly patient with risk factor for stroke. Also, normal EEG can't not rule out seizure, important medical facts, limb-shaking TIA does not affect face and does not follow the pattern of Jacksonian epilepsy, reduced cerebral perfusion was induced by hyperextension of the neck resulting in hemodynamic TIA, all investigation was normal and patient was diagnosed only after challenge with acetazolamide, In a busy neurology clinic, a thorough medical history might not be possible but in rare disease, examining the history carefully might save physician and patient a few unnecessary tests, time and help patient receiving the diagnosis and treatment in a timely manner.



## REFERENCES

1. Coull AJ, Lovett JK, Rothwell PM. Population based study of early risk of stroke after Transient ischemic attack or minor stroke: implications for public education and organization of services, *BMJ*,2004,328:326. Pmid:14744823.
2. Koudstaal PJ, van Gijn L, Schouten HJ, Staal A, Duivenvoorden HJ, Gerritsma JG, Kraaijeveld CL. Diagnosis of transient Ischemic attacks: improvement of interobserver agreement by a checklist in ordinary language. *Stroke* 1986;17:723-728 Pmid:3738956.
3. Furie KL, Kasner SE, Adams RJ, Albers GW, RL, Fagan SC et al: American heart association Stroke Council, Council On Cardiovascular Nursing, council on Clinical Cardiology and interdisciplinary Council on Quality of care and and outcome Research. Guidelines for prevention of stroke in patients with stroke or transient ischemic attack: a guideline of health care professional from the American Heart association on Stroke, 2011;42:227-276, (Google Scholar).
4. Forster A, Greibe M, Wolf M, et al. how to identify stroke mimics in patients eligible for intravenous thrombolysis? *J Neurol.* 2012;259:1347-53, (PubMed) (Google Scholar).
5. Rothwell PM, Eliasziw M, Gutnikov SA, Fox AJ, Taylor DW, M ayberg MR, Warlow CP, Barnett HJ, nalysis of pooled data from the randomized controlled trials of endarterectomy for symptomatic carotid stenosis *Lancet* 2003;2003;361:107-116.
6. Law CM. Bennett DA, Feigin VL, Rodgers A, Blood pressure and Stroke, an overview of published reviews, *Stroke*, 2004, 35:1024. Link (google Scholar).
7. Klijn CJ, Kappelle LJ, van Huffelen AC, Visser GH, ALGra A, Tulleken CA, et al, recurrent Ischemia in Symtomatic carotid Occlusion, Prognostic value of hemodynamic factors, *neurology*, 2000, 55:1806-1812, (PubMed)(Google Scholar),
8. Ali S, Khan MA, Khealani B. Limb- shaking Transient ischemic Attack, case report and review of literature, *BMC Neurol.* 2006;6:5(PMC free Article) (PubMed)(Google Scholar),
9. Taemichi TK, Young WL, Prohovnik I, Gitelman DR, Correll JW, Mohr JP, perfusion insufficiency in Limb-Shaking transient Ischemic Attacks, *Stroke*, 1990;21:341, ( PubMed)( Google Scholar).
10. Khan S, Chang E, Saniuk G et al, Bilateral Asymmetric Asterix as Limb-Shaking Transient Ischemic Attack in Bilateral Carotid Stenosis *J Stroke Cerebrovasc Dis*:2015, 24: e29-e30.